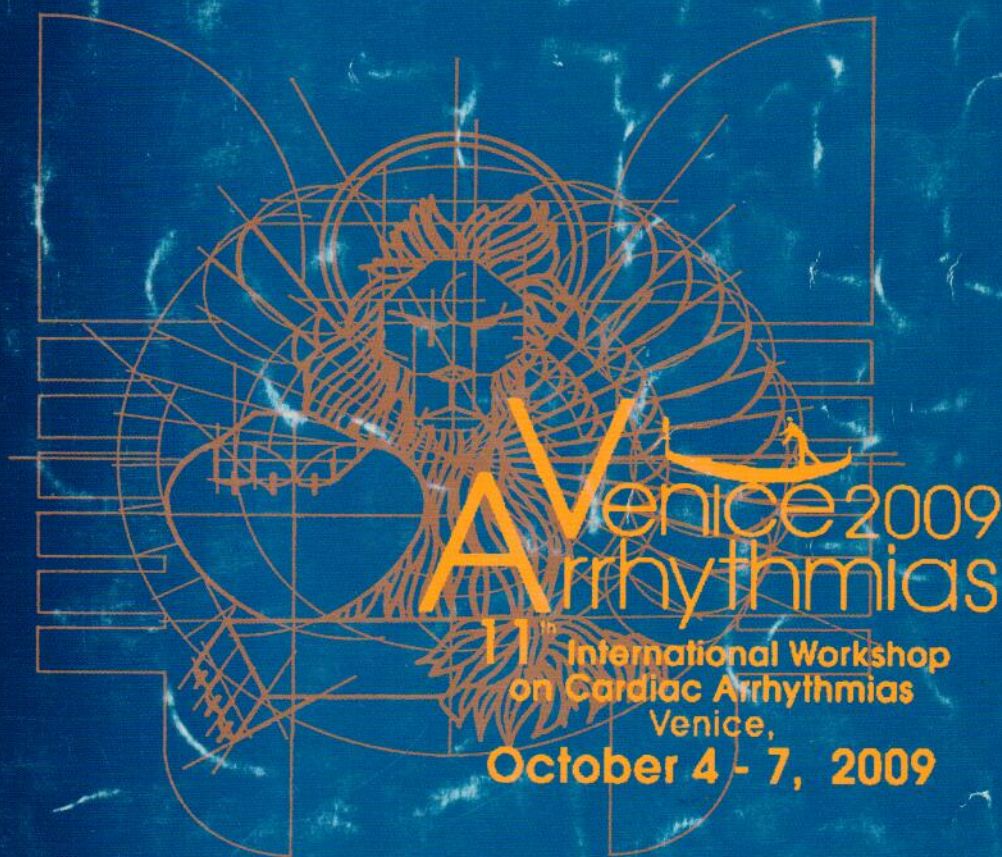


Journal of Cardiovascular Electrophysiology



AV Venice 2009
Arrhythmias

11th International Workshop
on Cardiac Arrhythmias
Venice,
October 4 - 7, 2009

ISSN:1045-3873



**WILEY-
BLACKWELL**

post-PTMV ($p = 0.517$). Only lateral RA showed significant DF increase post-PTMV (5.3 ± 1.76 to 6.13 ± 0.78 , $p = 0.041$). DF increased at posterior wall LA post-PTMV (6.2 ± 1.41 to 6.8 ± 0.56 , $p = 0.046$). The right superior PV (RSPV) demonstrated significant increase of DF post-PTMV (5.2 ± 2.26 to 6.1 ± 1.94 , $p = 0.044$).

Conclusion: The DF gradient of RA areas observed during high LA pressure was homogenized by LA pressure lowering. The DF of RA lateral wall, LA posterior wall and RSPV were increased by LA pressure lowering.

10.4 CORRELATION OF COMPLEX FRACTIONATED ATRIAL ELECTROGRAMS WITH THE SITES OF SINUS RHYTHM RESTORATION BY ABLATION IN LONGSTANDING PERSISTENT ATRIAL FIBRILLATION

M. Fiala, D. Wichterle, V. Bulková, J. Chovančík, J. Simek, M. Branny

Department of Cardiology, Heart Center, Hospital Podlesí, Třinec, Czech Republic

II. Department of Medicine, General Teaching Hospital, Prague, Czech Republic

Aims: To correlate location of complex fractionated electrograms (CFAEs) on the pre-ablation left and right atrial and coronary sinus 3-D maps with the ablation sites of AF conversion into atrial tachycardia (AT) and restoration of sinus rhythm (SR) in patients (pts) with longstanding persistent atrial fibrillation (LSPAF).

Methods: Maps were acquired in 33 pts (57 ± 8 years, persistent AF 32 ± 19 months) using CARTO software for automatic CFAE detection. In 21 pts with SR restored by ablation, distance of the nearest CFAE to the site of AT conversion (Distance AT) or SR restoration (Distance SR) was measured. Complex ablation was performed using plain anatomical 3-D maps.

Results: Distance AT was 26.6 ± 18.8 mm, and distance SR was 28.6 ± 13.9 mm. Distance AT ≤ 10 mm, resp. ≤ 20 mm was found in 4 (24%), and 6 (35%) pts; distance SR ≤ 10 mm, resp. ≤ 20 mm in 3 (14%), and 6 (29%) pts.

Conclusion: During ablation of LSPAF, there was weak correlation between CFAE and the sites of AT conversion or SR restoration in the majority of the pts. Supported by grant IGA MZ NS/9684-4/2008

10.5 COMPLETE ANTRAL ISOLATION OF THE PULMONARY VEINS BY THE BIG 28 MM CRYO-BALLOON CATHETER IN PATIENTS WITH PAROXYSMAL ATRIAL FIBRILLATION REGARDLESS OF ANATOMY INCLUDING COMMON TRUNKS

J.M. Paylos, C. Ferrero, A. Rey, A. Espejo, M.A. Quiñones, J.J. Veiga, J.L. Moreno

Unidad de Arritmias, Clínica Moncloa, Madrid, Spain

Methods used: Thirty eight pulmonary veins (PPVV) with 2 common trunks (28 and 29 mm sized) from 10 patients (7 male, 3 female, medium age 58.7 years), with normal atrial size and history of PAF were treated and frozen (-32° to -70°C) with a mean of 3.3 (1-6) number of ap-

plications, 300 sec duration, with the 28 mm Artic Front cryo-balloon-catheter at the antral vein level. Duo-decapolar circular catheter was used for PPVV cartography. Anticoagulation was kept over for 300 sec ACT. Integrity of the phrenic nerve (PN) was monitored by pacing during right PPVV cryothermal applications.

Summary of results: All (100%) PPVV, including common trunks were acute completed isolated with demonstration of entrance and exit block. In a 6-month follow-up, no patient (50% free of drugs) experienced arrhythmia, and no evidence of PPVV stenosis was found. No PN palsy occurred. Patients were discharged ≤ 72 hours post procedure.

Conclusions: Complete antral isolation of the PPVV (including common trunks) by the big cryo-balloon catheter is a feasible, efficient and safe method for the definitive therapeutic approach to cure PAF.

10.6 A COMBINED CRYOENERGY AND RADIOFREQUENCY APPROACH TO CATHETER ABLATION OF PERSISTENT ATRIAL FIBRILLATION: PRELIMINARY RESULTS FROM A PILOT STUDY

C. Tondo*, G.B. Forleo*, A. Pappalardo*, E.K. Heist**, A. Avella*, F. Laurenzi*, P. De Girolamo*, G. Bencardino*, A. Dello Russo*, M. Casella*, C. Barret**, J.N. Ruskin**, M. Mansour**

**Cardiac Arrhythmia and Heart Failure Research Institute, St. Camillo-Forlanini Hospital, Catholic University of Sacred Heart, Rome, Italy*

***Heart Center, Cardiac Arrhythmia Unit, Massachusetts General Hospital, Boston, MA, USA*

Introduction: We report the preliminary results of a study aimed to assess the feasibility of a combined cryoenergy and radiofrequency approach for ablation of patients with persistent AF.

Methods: Twelve consecutive patients (mean age 54.8 ± 14.4 years; 8 men) with highly symptomatic persistent AF referred for catheter ablation were included in this study. The procedure was performed in a stepwise manner. PV isolation was initially attempted with the cryoballoon ablation (28 or 23 mm in diameter; CryoCath). The Cryoablation was applied for 5 minutes at least 2 times for each vein. A circular multielectrode-mapping catheter positioned at the ostia of the PVs was used to confirm isolation. If AF was still present or inducible, complex electrograms (CFAE) in the left atrium and in coronary sinus were targeted for radiofrequency ablation with the use of a 3.5 mm cooled-tip catheter.

Results: With the cryoballoon approach, a total of 44 PVs including 2 veins with left common ostium were targeted and successfully isolated. In 2 right inferior PVs initially targeted with the 28 mm catheter, a second smaller 23-mm balloon was required before disconnection. The mean number of cryoablations for each patient was 9.3 ± 3.5 . Subsequently, in 6 patients atrial electrograms were mapped/analyzed during spontaneous or induced AF using an automated CFAE algorithm. No serious procedure-related complications were observed except for one phrenic nerve paralysis that occurred during ablation of the right superior PV, which resolved without any sequela within 12 hours. In this patient, all